

## Automated Detection of Optic Disc Using Fundus Image

T.R.GANESHBABU

Associate Professor, Electronics and Communication, Shri Andal Alagar College of Engineering, India  
ganeshbabutr@gmail.com

Received 10 December 2014 / Accepted 09 January 2015

---

*Abstract-Glaucoma is an eye disease which damages the optic nerve in the eye. It is the world second leading disease which causes blindness. It can be diagnosed through measurement of optic disc area. Fluid pressure within the eye rises which damages the optic nerve in the eye. Automatic calculation of optic disc boundary is challenging due to the interweavement of blood vessels with surrounding tissues around the disc. A variable level set algorithm of optic disc ellipse optimization improves the accuracy of boundary. The algorithm used is demonstrated on various data sets collected from Aravind Eye hospital from Pondicherry. The area of the optic disc obtained is better than the results of other data sets. This further leads to a large clinical evaluation of the algorithm involving various data sets.*

### I. INTRODUCTION

Glaucoma is one of the common causes of blindness. It causes progressive degeneration of optic nerve fibers and leads to structural changes of the optic nerve head and a simultaneous functional failure of the visual field. Since, glaucoma cannot be cured at final stage and leads to vision loss and cannot be restored, therefore its early detection and subsequent medical treatment is essential to prevent visual damage. Glaucoma is a condition that involves distinctive changes in the optic nerve and visual field. Optic nerve damage in the eye can ordinarily be alleviated and inhibited by sufficiently reducing intraocular pressure (IOP). Glaucoma is a disease of the major nerve of vision, called the optic nerve. The optic nerve receives light-generated nerve impulses from the retina and transmits to the brain, where we recognize these electrical signals as vision. If glaucoma is not diagnosed and treated, it leads to loss of vision. Glaucoma is the leading cause of blindness worldwide. In fact, as many as 6 million individuals are blind in both eyes from this disease. A watery material called aqueous humor is present in the eye. The aqueous humor is produced by the ciliary body and is drained through the Canal of Schlemm. If the aqueous humor does not drain out correctly, then pressure will build up in the eye. 3 million people in the United States have been affected by Glaucoma. Half of the people living do not know as such they are affected by the disease. The reason why people are unaware is, they do not know any symptoms and finally results in glaucoma.

### II. RELATED WORKS

Tracking and detection of retinal blood vessels in fundus images using a novel automated method is presented. A feature vector was computed utilizing multi scale analysis based on Gabor filters for every pixel in an image [1]. [3]A new template-based methodology for segmenting the OD from digital retinal images is presented. This methodology uses morphological and edge detection techniques followed by the Circular Hough Transform to obtain a circular OD boundary approximation. [5]The detection of the optic disc and macula for calculating the diameter of the optic disc and the distance between the optic disc and macula has been explained by using simple statistical techniques. 97% of the optic discs and macula is detected and located, and measured over 94% of the optic discs accurately. [6] An automatic CDR determination method using a variable level-set approach to segment the optic disc and cup from retinal fundus images is proposed. The method is a core factor of ARGALI, a scheme for programmed glaucoma risk consideration [7]. A system to detect OD and cup limit to get relevant disk restriction for glaucoma detection is presented. In general, the cup deformation is not uniform and the sector where the deformation occurs is also used by experts for glaucoma detection. The ellipse fitting strategy followed by the current methods to obtain the CDR is inadequate for this task. [11] A new method for the detection of glaucoma using fundus image which mainly affects the optic disc by increasing the cup size is proposed in paper. [13] Glaucoma is a chronic eye disease that leads to vision loss. As it cannot be cured, detecting the disease in time is important. Current tests using intraocular pressure (IOP) are not sensitive enough for population based glaucoma screening.

### III. DATASET

The retinal images used for this study were collected from the Aravind Eye Hospital, Pondicherry, India. All the images are stored in lossless JPEG format. The dataset contains fundus images. The fundus images consist of normal and glaucomatous images collected from infant to old subjects. The fundus camera, a microscope, and a light source are used to acquire the retinal images to diagnose diseases.

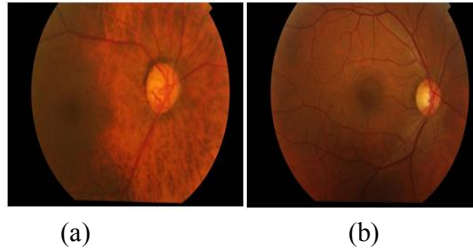


Figure.1 Typical Fundus Normal and Glaucoma Images

### IV. METHODOLOGY

Fundus image is used to determine any abnormality change in retina. They are captured by using special device called ophthalmoscopes. Automated detection of glaucoma can be performed by measuring the key characteristics features of Optic disc. Retinal images are captured by using a fundus camera. The automated scheme for determining optic disc is done by variable level set method.

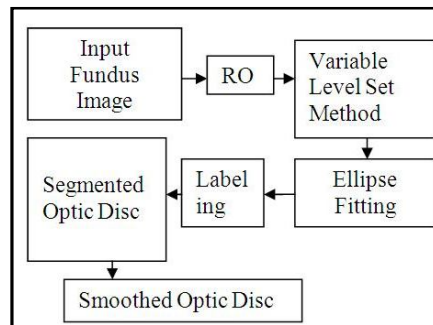


Figure.2 Determination of optic disc

#### a) Extraction of approximate region of interest

The Green plane (G) from the RGB fundus image is separated and it is considered for the analysis, because G plane provides best contrast than other two planes. Then the maximum brightest point within the optic disc in the G plane is determined. The approximate region of the optic disc is to be selected around this identified brightest point. After analyzing number of fundus images of size, it is decided that the brightest pixel as the centre point and this region is found to cover mainly the entire optic disc along with a small portion of other regions of the image.

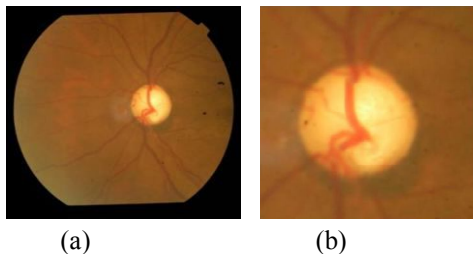


Figure.3 (a) Shows input fundus image and (b) shows the ROI with Optic Disc.

### b) Variable Level Set Method

The variable level set method (VLSM) is a numerical technique for tracking interfaces and shapes. The level set method can perform numerical computations involving curves and surfaces on a fixed Cartesian grid without having to parameterize these objects. The idea behind all level set algorithms is to represent the curve or surface in question at a certain time  $t$  as the zero level set (with respect to the space variables) of a certain function  $u(t, x)$ , the so called level set function

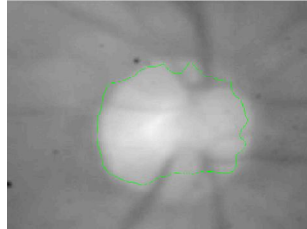


Figure.4 detection of optic disc using variable level set method

### c) Segmentation of optic disc

This ROI with optic disc image is used here to get the exact region of optic disc. Optic disc is frequently used to describe the portion of optic nerve clinically visible on examination. The bright yellowish or white region is the portion where optic disc appears in fundus image. Its shape is more or less circular, interrupted by blood vessels. Although sometimes due to the nature of the photographic projection, it has the form of an ellipse. In this work, the optic disc is segmented using Variable level set algorithm.

### d) Optic disc area calculation

After extracting the optic disc, elliptical fitting is been applied to smoothen the optic disc boundary. This method of elliptical fitting is described as follows. The labelling of components technique is applied to form the rectangle containing the whole disc region as shown below. The centroid of the rectangle is taken as a centre to draw an ellipse using “(1),” and “(2),” that inscribed in the rectangle as shown. The area of the ellipse is calculated by using “(3)”.

$$X=a*(\cos\alpha\cos\beta) -b*(\sin\alpha\sin\beta) \quad (1)$$

$$Y=a*(\cos\alpha\sin\beta) +b*(\sin\alpha\cos\beta) \quad (2)$$

Here  $\beta = 0$  and  $\alpha$  varies from  $0$  to  $360$

$$\text{Area} = \pi ab \quad (3)$$

Where  $a$  is the major axis length (half of the rectangle width) and  $b$  is the minor axis length (half of the rectangle height)




Figure.5. (a) and (b) Shows Labeling of optic disc region and smoothed elliptical boundary

## V. SOFTWARE REQUIREMENT

The operating system used is Windows 7 and the tool used is Matlab of version 7.10. MATLAB is a high-level technical computing language and interactive environment for algorithm developing, visualization of data, data analysis, and numerical computation. Matlab is a data analysis and visualization tool which has been designed with powerful support for

matrices and matrix operations. Matlab has excellent capabilities in graphics, and has its own powerful programming language. One of the reasons that Matlab has become such an important tool is through the use of sets of Matlab programs designed to support a particular task.

## VI. RESULTS AND DISCUSSION

In this paper, first the colour fundus image is taken as input and it is converted to gray-level images. Then, the feature extraction process is done for all input images. Then the classification of images is done to find normal and glaucoma affected images. The figure below shows the optic disc for normal image and glaucoma image.

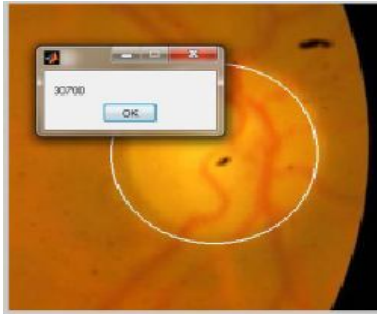

Figure.6 Shows the Optic Disc Area for normal image

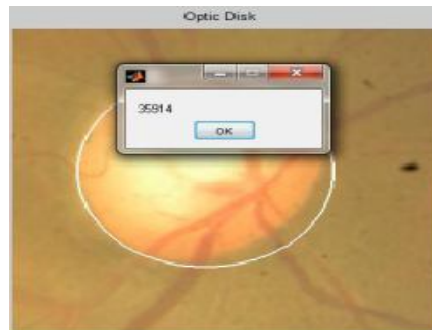

Figure.7 Shows the Optic Disc Area for abnormal image

Table 1

S.No	Normal Image	Glaucoma Image
1.	30700	35914
2.	23316	30743
3.	30465	23241
4.	301037	23968

The above table shows the optic disc area of normal and Glaucoma images.

## VII. CONCLUSION

This paper demonstrates the extraction of optic disc by using variable level set method based ellipse optimization algorithm for more accurate detection of optic disc. When compared with the results of other systems, this approach gives a better segmentation of disc which results to more accurate glaucoma diagnosis. The good performance of this new approach leads to a large scale databases. We conclude that our approach offer an efficient tool for enhancing diagnostic abilities and can add to the sensitivity of the existing technique to improve the performance. To improve the results a number of testing images and training can be increased.

## REFERENCES

- [1] Alireza Osareh, "An Automated Tracking Approach for Extraction of Retinal Vasculature in Fundus Images", *Journal of Ophthalmic and Vision Research*, vol.5, no.1, 2010.
- [2] Chih-Yin Ho, Tun Wen Pai, Hao-Teng Chang, Hsin-Yi Chen, "An automatic fundus image analysis system for clinical diagnosis of glaucoma" 2011 International Conference on Complex, Intelligent, and Software Intensive Systems pp(559-564).
- [3] Arturo Aquino, "Detecting the Optic Disc Boundary in Digital Fundus Images Using Morphological, Edge Detection, and Feature Extraction Techniques", *IEEE Transactions on Medical Imaging*, vol.29, no.11, November 2010.
- [4] Bouma, B 2001. "Handbook of Optical Coherence Tomography." 1<sup>st</sup> Edn. Dekker, New York.
- [5] Cemal Köse, "Statistical Techniques for Detection of Optic Disc and Macula and Parameters Measurement in Retinal Fundus Images", *Journal of Medical and Biological Engineering*, vol.31, no 6, pp 395-404, 2011. "Cup Segmentation for Glaucoma Screening", *IEEE transactions on medical imaging*, vol. 32, no. 6, June 2013.
- [6] D. W. K. Wong, "Level-Set Based Automatic Cup-To-Disc Ratio Determination Using Retinal Fundus Images in Argali", 30th Annual International IEEE EMBS Conference Vancouver, British Columbia, Canada, August 20-24, 2008.
- [7] Gopal Datt Joshi, "Optic Disk and Cup Boundary Detection Using Regional Information", *IEEE International Symposium on Biomedical Imaging: From Nano to Macro*, 2010.
- [8] [http://en.wikipedia.org/wiki/Fundus\\_photography](http://en.wikipedia.org/wiki/Fundus_photography).
- [9] T. Walter and J.C. Klein, "Automatic analysis of colour fundus photography and its application to the diagnosis of diabetic retinopathy", In *Handbook of biomedical image analysis*, Vol.2, pp 315-368, 2005.
- [10] Chih-Yin Ho, Tun Wen Pai, Hao-Teng Chang, Hsin-Yi Chen, "An automatic fundus image analysis system for clinical diagnosis of glaucoma", *International Conference on Complex, Intelligent, and Software Intensive Systems*, pp.559-564, 2011.
- [11] Jagadish Nayak, Rajendra Acharya U. P. Subbanna Bhat, Nakulshetty, Teik-cheng Lim "Automated Diagnosis of Glaucoma Using Digital Fundus Images", *Journal of Medical systems*, 2009.
- [12] Quigley, H. A., Broman, A. T., "The number of people with glaucoma worldwide in 2010 and 2020," *British Journal of Ophthalmology* (2006); 90:262.
- [13] Jun Cheng\*, Jiang Liu, Yanwu Xu, Fengshou Yin, Damon Wing Kee Wong, Ngan-Meng Tan, Dacheng Tao, Ching-Yu Cheng, Tin Aung, and Tien Yin Wong, "Superpixel Classification Based Optic Disc and Optic Cup Segmentation for Glaucoma Screening", 2013.